

PARASITIC INFESTATIONS IN HYBRID SURUBIM CATFISH FRY (*Pseudoplatystoma reticulatum* x *P. corruscans*)*

Santiago Benites de Pádua¹⁺, Márcia Mayumi Ishikawa², Rodrigo Yutaka Dichoff Kasai³,
Gabriela Tomas Jerônimo⁴ and Juliana Rosa Carrijo-Mauad⁵

ABSTRACT. Pádua S.B., Ishikawa M.M., Kasai R.Y.D., Jerônimo G.T., Carrijo-Mauad J.R. [Parasitic infestations in hybrid surubim catfish fry (*Pseudoplatystoma reticulatum* x *P. corruscans*)]. Infestações parasitárias em alevinos de surubim híbrido (*Pseudoplatystoma reticulatum* x *P. corruscans*). *Revista Brasileira de Medicina Veterinária*, 34(3):235-240, 2012. Centro de Aquicultura, Unesp (CAUNESP), Rod. Paulo Donato Castellane, s/n, Bairro Rural, Jaboticabal, SP 14884-900, Brazil. E-mail: santiagopadua@live.com

This study evaluated parasitic infestations in the hybrid surubim catfish (*Pseudoplatystoma reticulatum* ♀ x *P. corruscans* ♂) during the initial phase of rearing. 50 fish of lengths ranging from 5.7 to 20.3 cm and weights from 1.2 to 48.8 g were examined. Among the fish evaluated, only 15 (30%) were parasite-free, while at least one type of parasite was diagnosed in all of the other 35 (70%). Among these, the protozoan *Ichthyophthirius multifiliis*, *Epistylis* sp. and *Trichodina* sp. were observed. Occurrences of myxosporidians were seen, represented by *Henneguya* sp. and a metazoan belonging to the class Monogenoidea. The ciliated protozoa *I. multifiliis*, *Epistylis* sp. and *Trichodina* sp. were the main parasites infesting the gills and tegument of hybrid catfish fry. The peritrichid *Epistylis* sp. may be an emerging parasite in Brazil.

KEY WORDS. Fry, Ciliophora, Myxosporea, Monogenoidea.

RESUMO. Este estudo avaliou as infestações parasitárias que acometem alevinos de surubim híbrido (*Pseudoplatystoma reticulatum* ♀ x *P. corruscans* ♂) durante a fase inicial de criação. 50 peixes com tamanho variando de 5,7 a 20,3 cm e pesando de 1,2 a 48,8 g foram examinados. Entre os peixes examinados, somente 15 (30%) estavam livres de qualquer parasito e os demais apresentaram infestação por pelo menos um tipo de parasito 35 (70%). Entre estes, foram observados os protozoários *Ichthyophthirius multifiliis*, *Epistylis* sp. e *Trichodina* sp. Foram observados mixosporídeos, representado por *Henneguya* sp. e um metazoário pertencen-

te à classe Monogenoidea. Os protozoários ciliados *I. multifiliis*, *Epistylis* sp. e *Trichodina* sp. foram os principais parasitos que infestaram brânquia e tegumento de alevinos de surubim híbrido. O peritríquio *Epistylis* sp. pode tratar-se de um parasito emergente no Brasil.

PALAVRAS-CHAVE. Alevinos, Ciliophora, Myxosporea, Monogenoidea.

INTRODUCTION

The production of carnivorous catfish belonging to the native fauna of the Pantanal region has been increasing over recent years in Brazil. Among

*Received on December 1, 2011.

Accepted for publication on February 28, 2012

¹ Médico-veterinário. Centro de Aquicultura, Unesp (CAUNESP), Rod. Paulo Donato Castellane, s/n, Bairro Rural, Jaboticabal, SP 14884-900, Brasil. ⁺ Autor para correspondência. E-mail: santiagopadua@live.com

² Médica-veterinária, DSc. Embrapa Agropecuária Oeste, BR 163 km 253,6, Cx. Postal 661, Dourados, MS 79804-970, Brasil. E-mail: marcia@cpao.embrapa.br

³ Médico-veterinário, MSc. Pirai Piscicultura, Rua Abrão Julio Rahe, 1903, Vila Célia, Campo Grande, MS 79.020-190, Brasil. E-mail: rodrigokasai@hotmail.com

⁴ Engenheira de Aquicultura, MSc. Laboratório AQUOS, Sanidade de Organismos Aquáticos, Departamento de Aquicultura, Universidade Federal de Santa Catarina, Rod. Ademar Gonzaga, 1346, Florianópolis, SC 88040-900, Brasil. E-mail: gabriela@cca.ufsc.br

⁵ Médica-veterinária, DSc. Universidade Federal da Grande Dourados, Faculdade de Ciências Biológicas e Ambientais, Rodovia Dourados-Itaúma, km 12, Dourados, MS 79000-000. E-mail: julianacarrijo@ufgd.edu.br

the species of interest, there are some that are kept mainly for ornamental purposes, such as the jurupensém (*Sorubim lima*) and the jurupoca (*Hemisorubim platyrhynchos*), and others for which the main commercial appeal comes from their excellent organoleptic quality, which gives them high commercial value for human consumption. This latter group includes two main species, such as: pintado (*Pseudoplatystoma corruscans*) and cachara (*P. reticulatum*). When these two species are crossed artificially, a hybrid surubim catfish is obtained (*P. reticulatum* ♀ x *P. corruscans* ♂). Today, this hybrid is among the main fish produced in Central Brazil, and the product has been introduced into highly demanding international markets.

The technology for producing hybrid surubim catfish is still under development, and sanitary problems are a major factor responsible for diminished production. In this respect, parasitic diseases are very important, given that they can cause losses under conditions of intensive rearing (Pavanelli et al. 1998), especially through occurrences of deaths (Khan 2009). In addition, parasitic infestations in fry reared in larval systems are of fundamental epidemiological importance, given that future outbreaks at other phases of production may be associated with parasites acquired during this stage. Thus, periodic diagnoses and continual epidemiological surveillance should be implemented, along with strategic prophylactic measures, in order to have an effective sanitary program.

Studies on the fauna that parasitizes hybrid surubim catfish are scarce. *Henneguya pseudoplatystoma* was one of the first parasites described in these fish (Naldoni et al. 2009), while further information is limited to studies conducted on pintado and cachara. Machado et al. (1995) described occurrences of ten species of endohelminths in pintado from the Paraná River, comprising five species of cestodes and five of nematodes, although the cestodes were more prevalent. The parasites that have been found to affect this species in intensive rearing in the State of Mato Grosso do Sul are *Vancleaveus fungus* and *V. platensis* (Monogenoidea), *Tripartiella pseudoplatystomae* (Ciliophora) and *Henneguya* sp. (Myxosporidia) (Pinto 2008, Pinto et al. 2009). Among cachara caught in the Aquidauana River, in the Pantanal region of the State of Mato Grosso do Sul, 19 parasite species have been diagnosed, with predominance of proteocephalid cestodes (Campos et al. 2008).

Consolidation of the production chain for hybrid surubim catfish in Brazil depends, among other factors, on constant production of healthy fry in order to meet the demand for fish for fattening. For this, it is of fundamental importance to have knowledge of the diseases that affect these fish in rearing systems. Thus, the present study had the aim of evaluating the parasitic infestations that affect hybrid surubim catfish (*P. reticulatum* ♀ x *P. corruscans* ♂) during larval rearing.

MATERIAL AND METHODS

This study was conducted at a production unit for the initial juvenile stage of hybrid surubim catfish (larval rearing), located at the Municipality of Terenos (20°25'57.7" S; 55°17'08.9" W), in the State of Mato Grosso do Sul, Brazil. During April 2010, 50 fish of lengths ranging from 5.7 to 20.3 cm and weights from 1.2 to 48.8 g were caught in order to evaluate their infestation by parasites (Ethics Committee 23080.0 29979/2009-05/CEUA/UFSC). Over this period, the fish were going through a process of dietary conditioning, involving a gradual transition from natural food (wet diet) to commercial feed (dry diet).

The sampling was done in glass fiber tanks 1000 L of capacity and water renewal rate 14 L min⁻¹, and subsequently in raceways of 10 x 5 x 1.5 m, in which the fish received commercial feed. Fish tanks were cleaned every day to reduce the levels of organic residues, especially coming from leftover feed. This was a highly intensive production system, with a high density of stock and constant renewal of the water.

To make the diagnoses, fish were caught randomly with the aid of hand nets, anesthetized using clove oil (50 mg L⁻¹) and assessed macroscopically for the presence of signs of diseases. After these assessments, the fish were screened under a stereomicroscope. Mucus was collected by scraping the entire tegument and was mounted on slides. To diagnose the presence of gill parasites, the gill arches were carefully removed, separated and positioned on slides under coverslips together with 0.65% saline solution. These slides were examined under a light microscope for the possible presence of parasites. The fish were then necropsied, and fragments of liver, spleen, kidney and heart tissue were collected, compressed between slides and coverslips together with 0.65% saline solution and were evaluated under a light microscope. The entire gastrointestinal

tract was removed, saline solution warmed to 55° was added, and the material was fixed in 10% buffered formalin solution for subsequent investigation of endoparasites. The results from parasitological analyses were calculated according to Bush et al. (1997).

Before catching the fish for diagnosis, the physicochemical characteristics of water in which they were reared were monitored. Dissolved oxygen and temperature were measured by means of a digital oximeter (YSI 550[®]), and the hydrogen ion potential was measured by means of a pocket pH meter (YSI PH10[®]). Water samples were collected from the outflow in order to assay total ammonia, nitrite and nitrate by means of a colorimetric kit (Alfakit[®]). The means and standard deviations for these parameters were: dissolved oxygen 5.7 ± 1.0 mg L⁻¹, pH 7.4 ± 0.13 , temperature 23.1 ± 0.5 °C and total ammonia 0.4 ± 0.1 mg L⁻¹. Using this methodology, nitrate and nitrite were imperceptible.

RESULTS

Among the 50 fish evaluated, only 15 (30%) were completely free from any parasite, while at least one type of parasite was diagnosed in all of the other 35 fish (70%). Among these, the protozoans *Ichthyophthirius multifiliis*, *Epistylis* sp. and *Trichodina* sp. were diagnosed. In addition, the presence of myxosporidians was recorded, represented by *Henneguya* sp. and a metazoan belonging to the class Monogenoidea. The prevalence of each parasite diagnosed in the hybrid catfish during the initial phase of rearing is presented in table 1. Ciliated protozoa were the most prevalent type in this study, followed by myxosporidians and metazoa, with the same prevalence as each other.

In this study, *I. multifiliis*, *Trichodina* sp., and *Epistylis* sp. were found in skin, while *I. multifiliis*, *Trichodina* sp., Monogenoidea and *Henneguya* sp. were found in the gills. No parasite was observed in the internal organs.

Table 1. Parasitological analysis in the hybrid surubim catfish during the initial phase of rearing.

Parasites	EF/PF	P (%)	SI
<i>Ichthyophthirius multifiliis</i>	50/24	48	Skin, cornea and gills
<i>Epistylis</i> sp.	50/23	46	Fins and skin
<i>Trichodina</i> sp.	50/10	20	Skin, fins and gills
<i>Henneguya</i> sp.	50/1	2	Gills
Monogenoidea	50/1	2	Gills

EF: Examined fish; PF: Parasitized fish, P: prevalence, SI: Site of infestation.

Among the clinical signs that were observed in the parasitized fish, white spots in the fry parasitized by *I. multifiliis* can be highlighted. These were observed over the entire body surface, including the skin, fins and, in a few fish, the corneas. White spots were observed on the gill lamellae, gill slits and oral cavity. In addition, there was epithelial proliferation in the tegument affected by this parasite, which was seen using under the stereomicroscope during the screening procedures (Figure 1a-d). The sessile peritrichid *Epistylis* sp. caused focal lesions on the cranium and pectoral and dorsal fins, where occurrences of different levels of corrosion were seen, involving all of the support tissue of the structures affected (Figure 1e). No macroscopically abnormalities were observed in fry parasitized by *Trichodina*, *Henneguya* and Monogenoidea.

DISCUSSION

The protozoon *I. multifiliis* causes great losses during the initial phase of fry production around the world, especially when fry are reared in the subtropical and temperate zones, as observed in cyprinid *Barbus barbus*, *Chondrostoma nasus*, *Leuciscus cephalus* and *Aspius aspius*, which present prevalence rates between 10 and 40% (Navratil 1991). That result was similar to the findings from the present study on hybrid surubim catfish. This parasite is one of the main limitations on the production of South American catfish (*Rhamdia quelen*) in southern Brazil, especially during the first weeks of rearing (Carneiro et al. 2005), given that its life cycle is promoted when the water temperature is low. On the other hand, occurrences of this protozoa in fry reared in warm water have not been observed, such as in pirarucu (*Arapaima gigas*) in the Amazon region (Araújo et al. 2009). However, scaly fish seem to be more resistant to this ciliated protozoon than are leathery fish. Moreover, *I. multifiliis* is one of the main obstacles to the production of hybrid surubim catfish in the Central-Western Region of Brazil. It may cause massive mortality, as already seen during periods of lowered temperature (Ishikawa M.M. unpublished data).

The pathogenesis of infestation by *I. multifiliis* involves comprising of the tegument and gills, thereby causing lymphocytic infiltration and focal necrosis, as well as different levels of epithelial proliferation (Maki et al. 2001). When these tissue lesions become established in the gills, they cause the respiratory capacity to become diminished and,

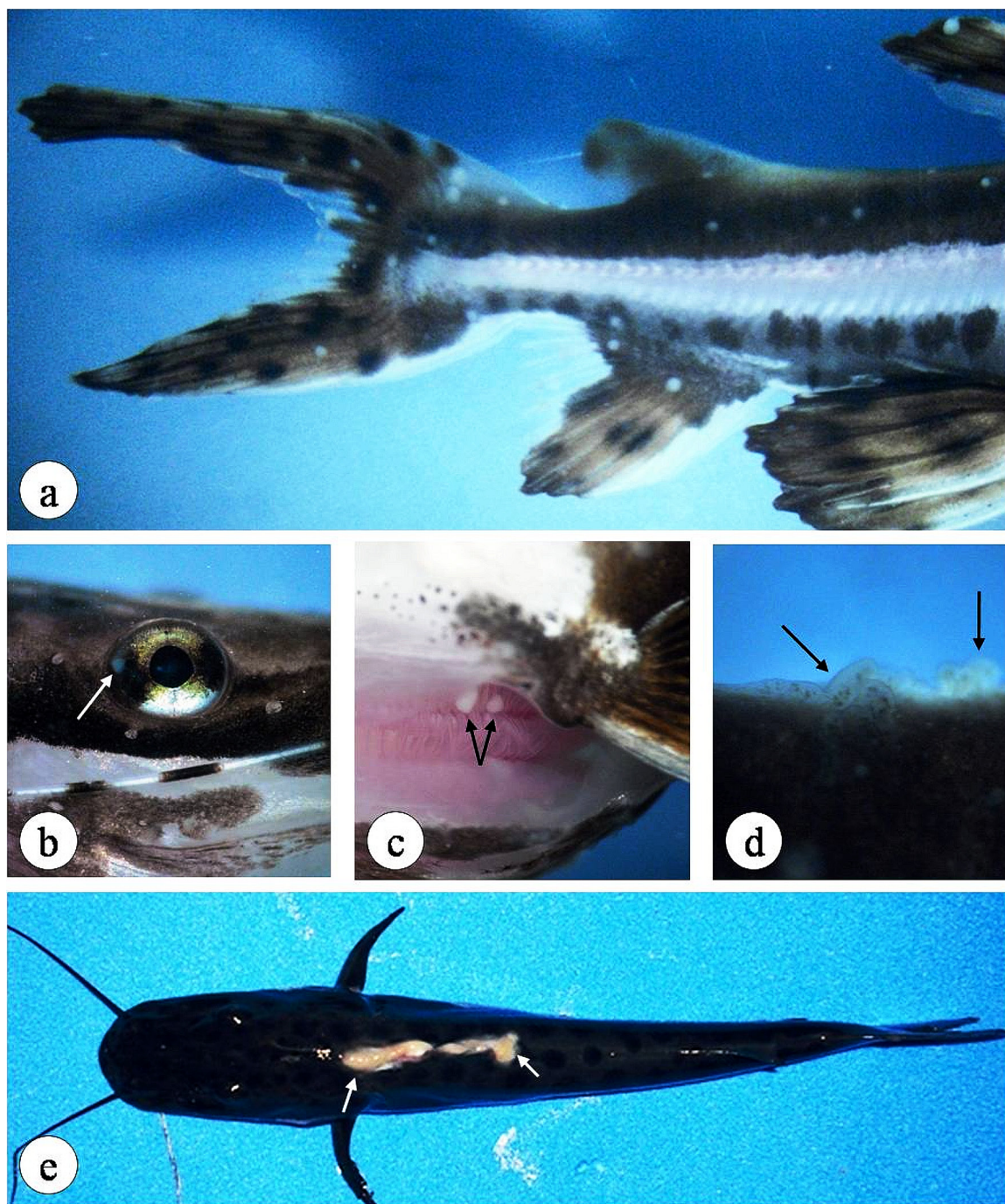


Figure 1. Clinical signs of ichthyophthiriasis and epistylis in the hybrid surubim catfish fry. White spots on the tegument and fins (a), cornea (b) and gill lamellae (c), and proliferation of epithelium on the tegument (d), caused by *I. multifiliis*. Optical stereomicroscope, 10X. Corrosion of dorsal fin, also affecting the cranium (e), caused by *Epistylis*, in a fry measuring 10 cm.

depending on the intensity of the parasitism, they may give rise to death among the fish due to asphyxia in association with opportunistic bacterial infections, since a continuity solution in the fish epithelium is formed.

In the Czech Republic, the sessile peritrich *Heteropolaria lwoffii* (formerly *Epistylis lwoffii*) was reported to cause infestation in the tegument of juveniles of *B. barbatus*, *C. nasus* and *A. aspius*, with

prevalences of 10, 45 and 25% respectively (Navrátil 1991). In the same study, it was observed that young individuals of the cyprinid *L. cephalus* had the greatest sensitivity to infestation by this protozoa, such that the gills and tegument of, respectively, 30% and 70% of the fish evaluated were affected. In the present study on hybrid surubim catfish, the only site for parasitism was the tegument, involving the cranial region and fins. No occurrences of this

parasite in the respiratory organs, as described by Navratil (1991), were observed in this study.

In hybrid tambatinga (*Colossoma macropomum* ♀ x *Piaractus brachypomus* ♂) in Venezuela, it was observed that 0.78% of the fish were parasitized by *Epistylis* sp. (Centeno et al. 2004). In Brazil, Martins et al. (2000) reported that *Epistylis* sp. caused infestations in piauçu (*Leporinus macrocephalus*), Nile tilapia (*Oreochromis niloticus*) and common carp (*Cyprinus carpio*), affecting 1% of the fish studied. The high prevalence rate of this parasite in the hybrid surubim catfish of the present study does not agree with the values in the literature for reared species in Latin America (Martins et al. 2000, Centeno et al. 2004). Thus, this may be an emerging parasite in Brazil. These peritrichs are ectocommensal epibionts, but are capable of causing significant disease in channel catfish *Ictalurus punctatus* (Hubert and Waner 1975) and in hybrid surubim catfish, as reported for the first time in the present study. However, the pathology of infestation by this parasite in species of tropical fish has not been completely elucidated.

Trichodinid protozoan are mobile peritrichids, and occurrences of *Tripartiella pseudoplatystomae* (Pinto et al. 2009) and *Trichodina heterodentata* (Martins et al. 2010) in reared catfish have been recorded in Brazil. These parasites may present seasonality, with variations in prevalence related to environmental changes, such as the water quality conditions (Hossain et al. 2008). These authors described occurrences of *Trichodina domerguei* and *T. reticulata* in the fry of cyprinids such as: *Hypophthalmichthys molitrix*, *Ctenopharyngodon idella*, *C. carpio*, *Catla catla*, *Labeo rohita*, *Cirrhinus mrigala* and *Puntius gonionotus*, with mean values of 80.67 and 45.67% respectively, as well as being the most prevalent parasites (Hossain et al. 2008). Those values are higher than what was found in the present study on hybrid surubim catfish, which in turn are higher than that was described by Martins et al. (2000) in reared species in Brazil and similar to the values described in relation to tambatinga reared in Venezuela (Centeno et al. 2004). These parasites may cause significant tissue lesions, especially in the respiratory organs, as well as causing outbreaks with high mortality among fry, as described in Atlantic cod fry (*Gadus morhua*) with infestation due to *Trichodina jadranica* (Khan 2009).

Infection by the myxosporidian *Henneguya pseudoplatystoma* is responsible for reduction in

the functional area for gas exchange in the gills, in juvenile hybrid surubim catfish reared in Brazil, among which an infection rate of 36.7% of the fish studied was described (Naldoni et al. 2009). That value was higher than that observed in the present study. In the life cycle of this parasite, the presence of plasmodia in the affected tissue of the host can be seen. These structures correspond to vegetative forms of varying size, which house many vegetative nuclei and germinative cells of the parasite (Békési et al. 2002). The plasmodia cause structural changes to the affected organs according to the intensity of the parasitism, and these changes are partly responsible for the pathogenesis of the infection. For some myxosporidians to complete their life cycle, they require intermediate hosts. These are generally benthonic oligochaetes, which are commonly found in fish ponds sediment (Békési et al. 2002). Thus, the low prevalence observed in the present study may be related to the environment in which the fish were kept during their rearing, *i.e.* a sediment-free environment, which would have made it difficult for oligochaetes to proliferate.

Flatworms belonging to the class Monogeneoidea are one of the main types of parasite that affect fish species produced in Brazil (Martins et al. 2000, Martins et al. 2002, Ghiraldelli et al. 2006, Araújo et al. 2009, Jerônimo et al. 2010). They are most pathogenic for fish during the larval, post-larval and fry stages (Onaka 2009), but their prevalence observed in the hybrid surubim catfish was not high when reported from other studies (Martins et al. 2000, Martins et al. 2002, Ghiraldelli et al. 2006, Hossain et al. 2008, Araújo et al. 2009, Jerônimo et al. 2011). The prevalence of these parasites in the present study was similar to that was described by Navratil (1991), in which flatworms were only diagnosed in one of the four fry species studied. The low prevalence in the present study may be related to the good condition of the water used for rearing the hybrid surubim catfish. Environmental quality parameters may influence the prevalence and intensity of the parasitism caused by flatworms. For this reason, Monogeneoidea have been used as important biomarkers of environmental quality in fish rearing systems (Jerônimo et al. 2011).

The parasitic fauna in the hybrid surubim catfish fry recorded in the present study differed from the parasites that affect pintado and cachara from natural environments (Machado et al. 1995, Campos et al. 2008), with predominance of the ciliated pro-

tozoa *I. multifiliis*, *Epistylis* sp. and *Trichodina* sp., although differences relating to age and environmental conditions may influence the occurrence and predisposition towards these parasitosis. Therefore, fry production units need to adopt rigorous sanitary controls, with the aim of putting into effect prophylaxis against these diseases in the nursery, with promotion of biosafety in the production system, and so that these parasitosis are not spread onwards to subsequent stages of hybrid surubim catfish rearing.

Acknowledgements. The authors thank CNPq, Aquabrazil/Embrapa and the Ministry of Fishing and Aquaculture for their financial support.

REFERENCES

- Araújo C.S.O., Gomes A.L., Tavares-Dias M., Andrade S.M., Belem-Costa A., Borges J.T., Queiroz M.N. & Barbosa M. Parasitic infections in pirarucu fry, *Arapaima gigas* Schinz, 1822 (Arapaimatidae) kept in a semi-intensive fish farm in Central Amazon, Brazil. *Vet. Arhiv.*, 79:499-507, 2009.
- Békési L., Székely C. & Molnár K. Atuais conhecimentos sobre Myxosporea (Myxozoa), parasitas de peixes: um estágio alternativo dos parasitas no Brasil. *Braz. J. Vet. Res. Anim. Sci.*, 39:271-276, 2002.
- Bush A.O., Lafferty K.D., Lotz J.M. & Shostak A.W. Parasitology meets ecology on its own terms: Margolis et al. revisited. *J. Parasitol.*, 83:575-583, 1997.
- Campos C.M., Fonseca V.E., Takemoto R.M. & Moraes F.R. Fauna parasitária de cachara *Pseudoplatystoma fasciatum* (Siluriforme: Pimelodidae) do rio Aquidauana, Pantanal Sul Mato-grossense, Brasil. *Acta Sci. Biol. Sci.*, 30:91-96, 2008.
- Carneiro P.C.F., Schorer M. & Mikos J.D. Tratamentos terapêuticos convencionais no controle do ectoparasita *Ichthyophthirius multifiliis* em jundiá (*Rhamdia quelen*). *Pesq. Agropec. Bras.*, 40:99-102, 2005.
- Centeno L., Silva-Acuña A., Silva-Acuña R. & Pérez J.L. Fauna ectoparasitaria associada a *Colossoma macropomum* y al híbrido de *C. macropomum* x *Piaractus brachypomus*, cultivados em el estado Desta Amacuro, Venezuela. *Bioagro*, 16:121-126, 2004.
- Ghiraldelli L., Martins M.L., Jerônimo G.T., Yamashita M.M. & Adamante W.B. Ectoparasites communities from *Oreochromis niloticus* cultivated in the State of Santa Catarina, Brazil. *J. Fish Aquat. Sci.*, 1:181-190, 2006.
- Hossain M.D., Hossain M.K., Rahman M.H., Akter A., Khanom D.A. Prevalence of ectoparasites of carp fingerlings at Santaher, Bogra. *Univ. J. Zool. Rajshahi Univ.*, 27:17-19, 2008.
- Hubert W.A. & Warner M.C. Control of *Epistylis* on channel catfish in raceways. *J. Wildl. Dis.*, 11:241-244, 1975.
- Jerônimo G.T., Speck G.M. & Martins M.L. First report of *Enterogyrus cichlidarum* Paperna 1963 (Monogeneoidea: Ancyrocephalidae) on Nile Tilapia *Oreochromis niloticus* cultured in Brazil. *Neotrop. Helminthol.*, 4:75-8, 2010.
- Jerônimo G.T., Speck G.M., Cechinel M.M., Gonçalves E.L.T. & Martins M.L. Seasonal variation on the ectoparasitic communities of Nile tilapia cultured in three regions in southern Brazil. *Braz. J. Biol.*, 71:365-373, 2011.
- Khan R.A. Parasites causing disease in wild and cultured fish in Newfoundland. *Icel. Agric. Sci.*, 22:29-35, 2009.
- Machado M.H., Pavanelli G.C. & Takemoto R.M. Influence of the type of environment and the hidrological level variation in the endoparasitic infrapopulations of *Pseudoplatystoma corruscans* and *Schizodon borelli* (Osteichthyes) of the high river Paraná. *Rev. Bras. Zool.*, 12:961-976, 1995.
- Maki J.L., Brown C.C. & Dickerson H.W. Occurrence of *Ichthyophthirius multifiliis* within the peritoneal cavities of infected channel catfish *Ictalurus punctatus*. *Dis. Aquat. Organ.*, 44:41-45, 2001.
- Martins M.L., Moraes F.R., Fujimoto R.Y., Onaka E.M., Nomura D.T., Silva C.A.H. & Schalch S.H.C. Parasitic infections in cultured freshwater fishes a survey of diagnosed cases from 1993 to 1998. *Rev. Bras. Parasitol. Vet.*, 9:23-28, 2000.
- Martins M.L., Onaka E.M., Moraes F.R., Bozzo F.R., Mello A., Paiva F.C. & Gonçalves A. Recent studies on parasitic infections of freshwater cultivated fish in the State of São Paulo, Brazil. *Acta Sci.*, 24:981-985, 2002.
- Martins M.L., Marchiori N., Nunes G. & Rodrigues M.P. First record of *Trichodina heterodontata* (Ciliophora: Trichodinidae) from channel catfish, *Ictalurus punctatus* cultivated in Brazil. *Braz. J. Biol.*, 70:637-644, 2010.
- Naldoni J., Arana S., Maia A.A., Ceccarelli P.S., Tavares L.E., Borges F.A., Pozo C.F. & Adriano E.A. *Henneguya pseudoplatystoma* n. sp causing reduction in epithelial area of gills in the farmed pintado, a South American catfish: Histopathology and ultrastructure. *Vet. Parasitol.*, 166:52-59, 2009.
- Navratil S. Parasitoses in the fry of selected freshwater fish species under the conditions of stripping and rearing. *Acta Vet. Brno*, 60:357-366, 1991.
- Onaka E.M. Principais parasitoses em peixes de água doce no Brasil, p.536-574. In: Tavares-Dias M. (Ed.), *Manejo e Sanidade de Peixes de Cultivo*. Macapá, Embrapa Amapá, 2009.
- Pavanelli G.C., Eiras J.C. & Takemoto R.M. *Doenças de Peixes Profilaxia, Diagnóstico e Tratamento*. 1ª ed. Editora UEM, Maringá, 1998. 264p.
- Pinto E. *Infecções parasitárias em pintados (Pseudoplatystoma corruscans, Agassiz 1829), em sistema de cultivo intensivo no município de Dourados, MS*. Dissertação (Ciências Veterinárias). Universidade Federal de Lavras, 2008. 45f. (Disponível at: < http://bibtede.ufla.br/tede//tde_busca/arquivo.php?codArquivo=1338>)
- Pinto E., Garcia A.M., Figueiredo H.C., Rodrigues M.P. & Martins M.L. Primeiro relato de *Tripartiella* sp. (Ciliophora: Peritrichia) em *Pseudoplatystoma corruscans* (Osteichthyes: Pimelodidae) cultivado no estado de Mato Grosso Do Sul, Brasil, com descrição de nova espécie. *Bol. Inst. Pesca*, 35:91-97, 2009.