


Bioprinting of 3D anatomical models of flat and long thoracic limb bones of domestic cats (*Felis catus* Linnaeus, 1758)

Bioimpressão de modelos anatômicos 3D de ossos planos e longos do membro torácicos de Gatos Domésticos (*Felis catus* Linnaeus, 1758)

Nathalia da Silva Ramos Elias¹, Helton Carlos Sabino Pereira², Antônio Francisco da Silva Lisboa Neto³, Erick Eduardo da Silveira⁴, Amilton César dos Santos⁵ & Antônio Chaves de Assis Neto^{6*} 

¹ Undergraduate in Veterinary Medicine, Faculdade de Medicina Veterinária e Zootecnia (FMVZ), Universidade de São Paulo (USP), São Paulo, SP, Brazil

² Biologist, Programa de Pós-Graduação em Anatomia dos Animais Domésticos e Silvestres (PPGAADS), FMVZ, USP, São Paulo, SP, Brazil

³ Veterinarian, DSc., PPGAADS, FMVZ, USP, São Paulo, SP, Brazil

⁴ Veterinarian, MSc., PPGAADS, FMVZ, USP, São Paulo, SP, Brazil

⁵ Biologist, DSc., FMVZ, USP, São Paulo, SP, Brazil

⁶ Veterinarian, DSc., FMVZ, USP, São Paulo, SP, Brazil

Abstract

Any technique that assists the study of anatomy is important for the development of learning because knowledge creates a fundamental connection to the clinical and surgical routine. Three-dimensional (3D) model printing has gained visibility by achieving similarities between the real model and the printed one. This work aimed to produce 3D-printed anatomical pieces which are true to the real parts of the flat (scapula) and long (humerus, radius and ulna) bones of the thoracic limb in cats. Domestic cat bones from the FMVZ-USP Veterinary Macroscopic Anatomy Laboratory collection were used to obtain the scanned images and prints of the 3D models. The obtained 3D models were similar to the real bones and included the anatomical particularities of the species. Anatomical details of the scapula, humerus, radius, and ulna were reliably obtained. This study produced digital and printed 3D anatomical models of the flat and long bones of the thoracic limb, which can be used interactively and dynamically to teach comparative and applied anatomy.

Keywords: three-dimensional anatomy; 3D scanning; teaching anatomy; veterinary medicine; educational models.

Resumo

Qualquer técnica que auxilie o estudo da anatomia é importante para o desenvolvimento de seu aprendizado, de maneira que o seu conhecimento crie uma conexão fundamental para a rotina clínica e cirúrgica. A impressão em modelo tridimensional (3D) tem ganhado visibilidade por alcançar semelhanças entre o modelo real e o impresso. Esse trabalho teve como objetivo produzir peças anatômicas impressas 3D fiéis às peças reais dos ossos planos (escápula) e longos (úmero, rádio e ulna) do membro torácico de gatos. Ossos de gato doméstico pertencente ao acervo do Laboratório de Anatomia Macroscópica Veterinária da FMVZ-USP foram utilizados para obter as imagens escaneadas e impressões dos modelos 3D. As réplicas obtidas mostraram-se similares aos ossos reais quanto as particularidades anatômicas da espécie. Detalhes anatômicos da escápula, úmero, rádio e ulna foram obtidos de forma fidedigna. Além do mais, o presente estudo produziu modelos anatômica tridimensional digitais e impressos dos ossos planos e longos do membro torácico, que podem ser utilizados de forma interativa e dinâmica capazes de ser utilizadas a favor do ensino da anatomia comparada e aplicada.

Palavras-chave: anatomia tridimensional; digitalização 3D; ensino da anatomia; medicina veterinária; modelos educacionais.




How to cite: Elias N. S. R., Pereira, H. C. S., Lisboa Neto, A. F. S., Silveira, E. E., Santos, A. C., & Assis Neto, A. C. (2021). Bioprinting of 3D anatomical models of flat and long thoracic limb bones of domestic cats (*Felis catus* Linnaeus, 1758). *Brazilian Journal of Veterinary Medicine*, 43, e106020. <https://doi.org/10.29374/2527-2179.bjvm106020>

Received: July 04, 2019.

Accepted: October 20, 2020.

*Correspondence

Antônio Chaves de Assis Neto
Departamento de Cirurgia, Faculdade de Medicina Veterinária e Zootecnia, Universidade de São Paulo – USP
Av. Prof. Orlando Marquês de Paiva, 87, Butantã
CEP 05508 270 - São Paulo (SP), Brasil
E-mail: antonioassis@usp.br

 Copyright Elias et al. This is an Open Access article distributed under the terms of the Creative Commons Attribution Non-Commercial License which permits unrestricted non-commercial use, distribution, and reproduction in any medium provided the original work is properly cited.

Introduction

Three-dimensional (3D) printing has been applied in several fields, including engineering, art, industry and medicine (Hadeed et al., 2018; Matozinhos et al., 2017) and as educational models (Alcântara et al., 2019; Cui et al., 2017; Hackmann et al., 2019; Reis et al., 2017).

The 3D printing of compatible biomaterials and tissue media components is already a reality. A biomodel is a faithful representation of morphological characteristics, which can be virtual or physical. The use of 3D technology in the field of medicine and veterinary medicine is an important tool to assist in the detailed study of anatomy (Li et al., 2018) and for surgical planning (Cone et al., 2017).

The constant challenge of innovating the teaching of anatomy and discussing ethical issues related to the use of animals is in line with the concept of the 3Rs, which advocates the use of animals for teaching and research, based on three principles: Replacement, Reduction and Refinement (Pereira et al., 2017).

This work aimed to create a digital 3D anatomical collection and 3D print of flat and long bone models of the thoracic limb of domestic cats for interactive and dynamic uses and with great potential to be used in an educational environment.

Materials and methods

Anatomical parts

The bones used as digitization models belonged to the collection of the Laboratory of Veterinary Macroscopic Anatomy of the School of Veterinary Medicine and Animal Science of the University of São Paulo (*Faculdade de Medicina Veterinária e Zootecnia da Universidade de São Paulo - FMVZ-USP*). The bones had been previously prepared according to procedures established by Rodrigues (2005). The anatomical descriptions were based on the International Committee on Veterinary Gross Anatomical Nomenclature (2017).

3D scanning and editing

The bones were scanned separately using a “Go! 3D Scan” portable 3D scanner (Creaform Inc. Lévis, Quebec, Canada). The following parameters were used for the images: resolution of 0.5 mm, Optimize Scan Mesh and Decimate Scan Mesh between 80 and 100, Auto-fill Holes between 20 and 40 and Removes Isolated Patches between 20 and 25. Image capture was managed through a Software data acquisition and scanner interface, the program VXEelements 6.1® (Lévis, Quebec, Canada), which allows visualization of scanned images.

The images obtained were saved and edited in the Geomagic 12.1® program (Cary, NC, USA), which enables the operator to join images, correct faults, change color, smooth surfaces, and shape edges. This step was performed when it was not possible to scan the entire bone in a single file, requiring more than one file of the same bone and then joining them in the editor. The prints of each bone took approximately 8 hours, the scanning procedures took 30 minutes, and the total cost per printed model was around R\$ 40.00.

3D printing procedure

The best images obtained after scanning and editing were printed on a Stratasys Mojo Printer® 3D Printer (Rehovot, Israel) with printing capability using FDM (Fused Deposition Modeling) filament-shaped thermoplastic.

Results

The 3D models were created according to the specifications of the actual bones. Figures 1-4 demonstrate a comparative anatomical correspondence of a real bone and 3D model of the scapula, humerus, radio and ulna.

Anatomical details can be easily identified in 3D scanned models. The spine of the scapula lies on the lateral side of the scapula in its middle region, which separates the two fossae (supra and infraspinatus) (Figures 1A, B, C). The suprahamate and hamate processes (Figures 1A, B, C), supraglenoid tubercle (Figures 1A, C), subscapular fossa, and coracoid process (Figures 1D-F) can be observed and are represented in the printed models.

The head of the humerus (Figures 2A, C), lesser and greater tubercles (Figures 2D-F), deltoid tuberosity, medial part of the humerus (trochlea) and lateral portion (capitulum) (Figures 2D-F), condyles (Figures 2A-C), and lateral and medial epicondyles (Figures 2A-C) are easily identified in 3D-printed models.

Other structures can be easily evidenced and compared on real and 3D-printed bones. A depression can be observed on the caudal face of the distal epiphysis, the olecranon fossa, which articulates with part of the olecranon (Figures 2A-C). At the distal end on the cranial face there is also a depression, near the trochlea, that lodges the head of the radius when the elbow is flexed. Further, a supracondylar foramen can be seen in the distal epiphysis of the humerus (Figures 2D-F), proximal to the medial epicondyle.

The tuberosity of the olecranon can be observed at the proximal end of the ulna and trochlear notch at the base of the olecranon, which supports the articulation of the humerus. The anechoic process can be found in the cranial notch in the cranial direction. At the distal end of the ulna, the projection of a lateral styloid process is observed, which articulates with the radius (Figures 3D-F).

The head, neck and radial tuberosity can be observed on the actual and printed 3D or scanned radius (Figures 4A-C). At the distal end, the trochlea and ulnar notch can be observed. On the medial surface, the radius extends to form the radial styloid process (Figures 4D-F).

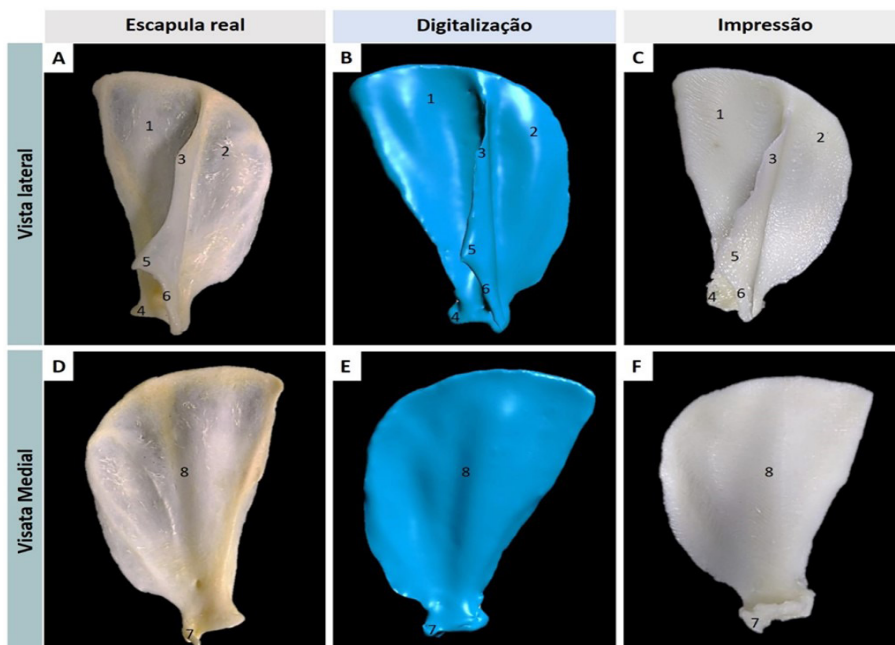


Figure 1. Comparison of the cat scapula in lateral and medial view of the real, digitized, and printed models, showing: the infraspinous fossa (1); supraspinous fossa (2); scapular spine (3); supraglenoid tubercle (4); suprahamate process (5); hamate process (6); coracoid process (7); and subscapular fossa (8).

Escapula real = Actual scapula; Digitalização = Digitized; Impressão = Printed; Vista Lateral = Side View; Vista Medial = Medial View.

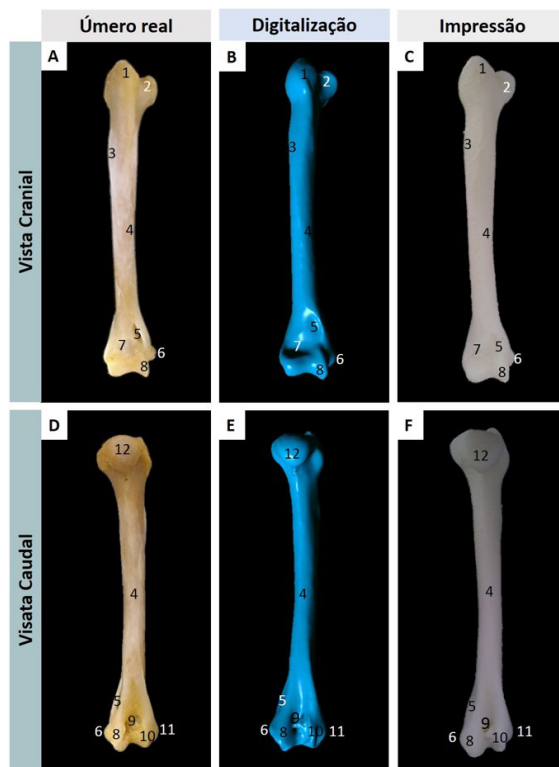


Figure 2. Comparison of cat humerus in cranial and caudal view of the actual, digitized and printed models, indicating: the greater tubercle (1); lesser humerus tubercle (2); deltoid tuberosity (3); humerus body (4); supracondylar foramen (5); medial epicondyle (6); radial fossa (7); capitulum (8); olecranon fossa (9); trochlea (10); lateral epicondyle (11); head of the humerus (12).

Úmero real = Actual humerus; Digitalização = Digitized; Impressão = Printed; Vista Cranial = Cranial View; Vista Caudal = Caudal View.

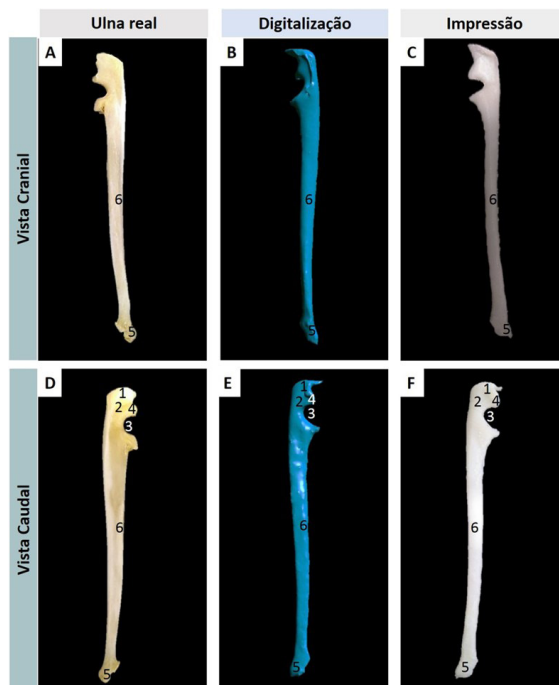


Figure 3. Comparison of cat ulna in lateral and medial view of the real, digitized and printed models, showing: the tuberosity of the olecranon (1); olecranon (2); trochlear notch (3); anconeal process (4); ulnar styloid process (5); body of ulna (6).

Ulna real = Actual ulna; Digitalização = Digitized; Impressão = Printed; Vista Cranial = Cranial View; Vista Caudal = Caudal View.

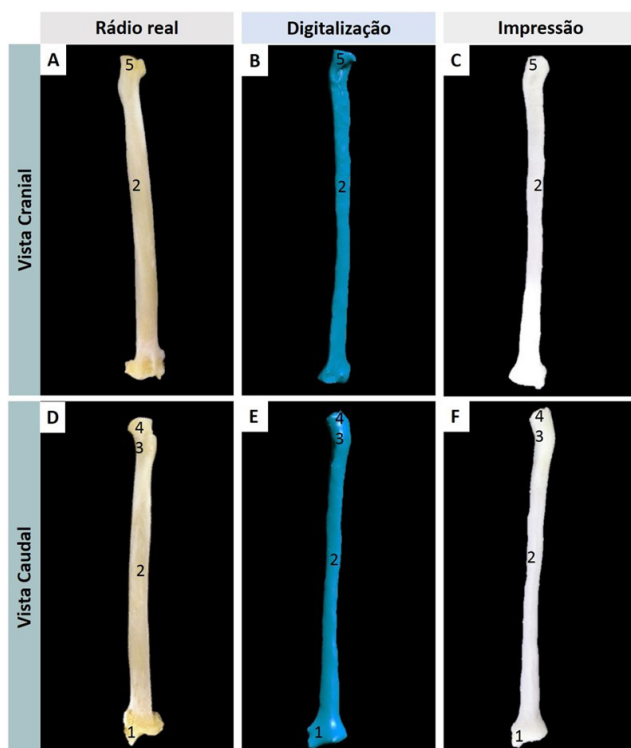


Figure 4. Comparison of the cat radius in cranial and caudal view of the real, digitized and printed models, indicating the styloid process of the radius (1), body of radius (2), neck of radius (3), head of radius (4), radial tuberosity (5). **Rádio real=Actual radius; Digitalização= Digitized; Impressão=Printed; Vista Cranial=Cranial View; Vista Caudal=Caudal View**

Discussion

This study describes an important method for producing accurate educational models of skeletal elements using a portable scanner and a 3D printer. The most prominent anatomical characteristics of the real bones were replicated in a reliable manner, except for tiny anatomical structures such as foramina. Nevertheless, Thomas et al. (2016) reported that this limitation does not interfere with the quality of printed materials and can be improved upon following the printing of good quality models.

As shown in this study, 3D-printed models are able to complement anatomy classes that are based only on traditional methods such as the use of cadaveric models. Moreover, they can serve as references for studies involving orthopedic surgical planning (Cone et al., 2017).

After the appropriate investment in scanning and printing equipment, the costs related to producing anatomical models are lower than the cost of purchasing or producing plastinated specimens (McMenamin et al., 2014). As in this study, Li et al. (2018) stated that all educators can produce useful 3D models in a relatively quick and easy manner after minimal operational training in the use of the 3D scanners and printers.

Printed models serve as a basis for describing and evaluating the replicated anatomical structures of a real specimen. However, although several studies demonstrate the importance of the use of 3D models, whether for surgical planning (Burzyńska et al., 2016; Kim et al., 2018; Mukherjee et al., 2017; Oxley, 2018; Silva & Gamarra-Rosado, 2014) or teaching (Dorbandt et al., 2017; Schoenfeld-Tacher et al., 2017; Suñol et al., 2019) the efficacy of this tool in veterinary medical practice still requires validation in future studies.

The production of bone replicas (bone biomodels) and organs from dogs, cats, horses, cattle and pigs using real mold scan or segmentation by computed tomography and 3D printing resonance is already a reality (Reis et al., 2019). Our experience with these models demonstrates the use of an innovative and high level of technological development for the rapid manufacturing of 3D-printed organ models using 3D scanning and printing technologies. Such models can then

be used for teaching of veterinary anatomy, with the potential for expansion into other areas of veterinary medicine such as pathology, surgery (surgical planning), use of prostheses for animal rehabilitation and imaging studies (Reis et al., 2019). The use of printed and virtual models will complement teaching practices in these areas. Further, given the degree of similarity to the original bones, their use in teaching is likely to be very effective.

Conclusion

This study enabled the creation of interactive models for the anatomical study of long bones and planes of the thoracic limbs of cats, which can be continuously optimized. Thus, these digitized and printed bone models can contribute to future studies aiming to validate the use of 3D-printed models in the context of anatomy teaching and as a complement to the use of cadaveric anatomical specimens.

Acknowledgements

The authors wish to acknowledge the contributions to the *Programa Unificado de Bolsa/USP*, CNPq and CAPES for research assistant scholarship.

Ethics statement

The project has been approved at the Animal Use Ethics Committee of the Veterinary School of Veterinary Medicine and Animal Science of University of Sao Paulo with protocol number 6323261119.

Financial support

NSRE - Received scholarship from CNPq (Conselho Nacional de Desenvolvimento Científico e Tecnológico) and Programa Unificado de Bolsa (PUB) of USP. HCS, AFSLN and EES - Received scholarship from CAPES (Coordenação de Aperfeiçoamento de Nivel Superior). ACS - Received scholarship from FAPESP (Fundação de Apoio à Pesquisa do Estado de São Paulo).

Conflicts of interest

NSRE, HCS, AFSLN, EES, ACS and ACAN - No conflict of interest.

Author's contributions

NSRE, HCS, AFSLN, ACS and ACAN - Development of methodology. Preparation and writing the initial draft. HCS, EES e ACAN - Writing, review and editing manuscript. CAN - Acquisition of the financial support for the project leading to this publication

Availability of complementary results

Non applicable.

The study and was carried out at Laboratory at Veterinary Macroscopy Anatomy of the University of Sao Paulo, São Paulo, Brazil. Data analysis was performed at School of Veterinary Medicine and Animal Sciences, São Paulo, Brazil.

References

- Alcântara, B.M., Silveira, E.E., Pereira, H.C.S., Lisboa Neto, A.F.S., Santos, A.C., & Assis Neto, A.C. (2019). Digitalização e impressão tridimensional como uma ferramenta para estudo anatômico e ortopédico dos ossos da pelve e longos do membro pélvico de cães. *Acta Scientiae Veterinariae*, 47, 1653. <https://dx.doi.org/10.22456/1679-9216.91076>.
- Burzyńska, K., Morasiewicz, P., & Filipiak, J. (2016). The use of 3D printing technology in the Ilizarov Method Treatment: Pilot study. *Advances in Clinical and Experimental Medicine*, 25(6), 1157-1163. <http://dx.doi.org/10.17219/acem/64024>. PMID:28028968.
- Cone, J. A., Martin, T. M., Marcellin-Little, D. J., Harrysson, O. L. A., & Griffith, E. H. (2017). Accuracy and repeatability of long-bone replicas of small animals fabricated by use of low-end and high-end commercial three-dimensional printers. *American Journal of Veterinary Research*, 78(8), 900-905. <http://dx.doi.org/10.2460/ajvr.78.8.900>. PMID:28738005.

- Cui, H., Nowicki, M., Fisher, J. P., & Zhang, L. G. (2017). 3D bioprinting for organ regeneration. *Advanced Healthcare Materials*, 6(1), 1601118. <http://dx.doi.org/10.1002/adhm.201601118>. PMID:27995751.
- Dorbandt, D. M., Joslyn, S. K., & Hamor, R. E. (2017). Three-dimensional printing of orbital and peri-orbital masses in three dogs and its potential applications in veterinary ophthalmology. *Veterinary Ophthalmology*, 20(1), 58-64. <http://dx.doi.org/10.1111/vop.12352>. PMID:26801834.
- Hackmann, C. H., Dos Reis, D. A. L., & Assis Neto, A. C. (2019). Digital revolution in veterinary anatomy: Confection of anatomical models of canine stomach by scanning and three-dimensional printing (3D). *International Journal of Morphology*, 37(2), 486-490. <http://dx.doi.org/10.4067/S0717-95022019000200486>.
- Hadeed, K., Acar, P., Dulac, Y., Cuttone, F., Alacoque, X., & Karsenty, C. (2018). Cardiac 3D printing for better understanding of congenital heart disease. *Archives of Cardiovascular Diseases*, 111(1), 1-4. <http://dx.doi.org/10.1016/j.acvd.2017.10.001>. PMID:29158165.
- International Committee on Veterinary Gross Anatomical Nomenclature. (2017). *Nomina anatómica veterinária*. (5th ed.). Editorial Committee.
- Kim, S. E., Shim, K. M., Jang, K., Shim, J. H., & Kang, S. S. (2018). Three-dimensional printing-based reconstruction of a maxillary bone defect in a dog following tumor removal. *In Vivo*, 32(1), 63-70. <http://dx.doi.org/10.21873/invivo.11205>. PMID:29275300.
- Lí, F., Liu, C., Song, X., Huan, Y., Gao, S., & Jiang, Z. (2018). Production of accurate skeletal models of domestic animals using three-dimensional scanning and printing technology. *Anatomical Sciences Education*, 11(1), 73-80. <http://dx.doi.org/10.1002/ase.1725>. PMID:28914982.
- Matozinhos, I. P., Madureira, A. A. C., Silva, G. F., Madeira, G. C. C., Oliveira, I. F. A., & Corrêa, C. R. (2017). Impressão 3D: Inovações no campo da Medicina. *Revista Interdisciplinar Ciências Médicas*, 1(1), 143-162.
- McMenamin, P. G., Quayle, M. R., McHenry, C. R., & Adams, J. W. (2014). The production of anatomical teaching resources using three-dimensional (3D) printing technology. *Anatomical Sciences Education*, 7(6), 479-486. <http://dx.doi.org/10.1002/ase.1475>. PMID:24976019.
- Mukherjee, P., Cheng, K., Flanagan, S., & Greenberg, S. (2017). Utility of 3D printed temporal bones in pre-surgical planning for complex BoneBridge cases. *European Archives of Oto-Rhino-Laryngology*, 274(8), 3021-3028. <http://dx.doi.org/10.1007/s00405-017-4618-4>. PMID:28540513.
- Oxley, B. (2018). A 3-dimensional-printed patient-specific guide system for minimally invasive plate osteosynthesis of a comminuted mid-diaphyseal humeral fracture in a cat. *Veterinary Surgery*, 47(3), 445-453. <http://dx.doi.org/10.1111/vsu.12776>. PMID:29446490.
- Pereira, G. G., Diéguez, J., Demirbas, Y. S., & Menache, A. (2017). Alternatives to animal use in veterinary education: A growing debate. *Ankara Üniversitesi Veteriner Fakültesi Dergisi*, 64(3), 235-239. <http://dx.doi.org/10.1501/Vetfak.0000002804>.
- Reis, D. A. L., Gouveia, B. L. R., Alcântara, B. M., Saragiotto, B. P., Baumel, É. E. D., Ferreira, J. S., Rosa Júnior, J. C., Oliveira, F. D., Santos, P. R. S., & Assis Neto, A. C. (2017). Biomodelos ósseos produzidos por intermédio da impressão 3D: Uma alternativa metodológica no ensino da anatomia veterinária. *Revista de Graduação USP*, 2(3), 47-53. <http://dx.doi.org/10.11606/issn.2525-376X.v2i3p47-53>.
- Reis, D. A. L., Gouveia, B. L. R., Rosa Junior, J. C., & Assis Neto, A. C. (2019). Comparative assessment of anatomical details of thoracic limb bones of a horse to that of models produced via scanning and 3D printing. *3D Printing in medicine*, 5, 13.
- Rodrigues, H. (2005). *Técnicas anatômicas*. (3a ed.). Arte Visual.
- Schoenfeld-Tacher, R. M., Horn, T. J., Scheviak, T. A., Royal, K. D., & Hudson, L. C. (2017). Evaluation of 3D additively manufactured canine brain models for teaching veterinary neuroanatomy. *Journal of Veterinary Medical Education*, 44(4), 612-619. <http://dx.doi.org/10.3138/jvme.0416-080R>. PMID:28534721.
- Silva, F., & Gamarra-Rosado, V. O. (2014). Biomodelagem virtual para diagnóstico e planejamento cirúrgico usando softwares livres. *Informática na Educação: Teoria & Prática*, 17(1), 125-143. <https://doi.org/10.22456/1982-1654.38000>.
- Suñol, A., Aige, V., Morales, C., López-Beltran, M., Feliu-Pascual, A. L., & Puig, J. (2019). Use of three-dimensional printing models for veterinary medical education: Impact on learning how to identify canine vertebral fractures. *Journal of Veterinary Medical Education*, 46(4), 523-532. <http://dx.doi.org/10.3138/jvme.0817-109r>. PMID:30418815.
- Thomas, D. B., Hiscox, J. D., Dixon, B. J., & Potgieter, J. (2016). 3D scanning and printing skeletal tissues for anatomy education. *Journal of Anatomy*, 229(3), 473-481.