

# Pulmonary stenosis in a dog submitted to valvuloplasty: case report

Estenose pulmonar em cão submetido à valvoplastia: relato de caso

Bruno Ricardo Soares Alberigi da Silva<sup>1\*</sup>, Nathália Marques de Oliveira Lemos<sup>2</sup>, Nicole Vallejo Correa dos Santos<sup>3</sup>, Julielton de Souza Barata<sup>4</sup> & Alexandre José Rodrigues Bendas<sup>5</sup>

<sup>1</sup>Veterinary, MSc, Professor. Universidade Castelo Branco – UCB, Rio de Janeiro, RJ, Brasil

<sup>2</sup>Veterinary, MSc, Resident in Cardiology and Respiratory Diseases. Hospital Veterinário, Universidade Federal Rural do Rio de Janeiro – UFRRJ, Seropédica, RJ, Brasil

<sup>3</sup>Undergraduate veterinary student. Universidade Castelo Branco – UCB, Rio de Janeiro, RJ, Brasil

<sup>4</sup>Veterinary, MSc. Universidade Castelo Branco – UCB, Rio de Janeiro, RJ, Brasil

<sup>5</sup>Veterinary, Doctorate, MSc. Programa de Pós-graduação em Medicina veterinária (Clínica e Reprodução Animal), Universidade Federal Fluminense – UFF, Niterói, RJ, Brasil

## Abstract

The Congenital heart diseases are characterized by morphological defects in the embryonic development and the most frequent in dogs are: pulmonary and aortic valve stenosis, ventricular septal defect and persistent ductus arteriosus. They may occur asymptotically or even evolve to congestive heart failure. The definitive diagnosis is made through the visualization of the alterations in the echocardiogram. In the present report, a French Bulldog, three months old, asymptomatic was presented to a private Veterinary practice in Rio de Janeiro, Brazil. Cardiac auscultation evidenced a systolic heart murmur in tricuspid focus and diastolic murmur in pulmonary focus. To better evaluate the dog chest radiography, electrocardiogram and echocardiogram were performed and allowed the diagnosis of pulmonary stenosis. The clinical treatment with beta-blocker was installed and the surgical procedure was performed with the balloon valvuloplasty. After the surgical treatment, the pressure gradient was gradually normalized, the use of atenolol was discontinued, and the patient was followed up for three years, remaining clinically stable throughout this time. The aim of this study was to report a case of pulmonary artery stenosis in a puppy, treated clinically and surgically, emphasizing the importance of the physical and complementary cardiologic exams.

**Keywords:** cardiac auscultation, beta-blocker, malformation, congenital heart disease, echocardiogram.

## Resumo

As Cardiopatias congênitas são caracterizadas por defeitos morfológicos no desenvolvimento embrionário, sendo as de maior ocorrência em cães as estenoses de valva pulmonar e aórtica, comunicação interventricular e persistência do canal arterial. Podem cursar de forma assintomática ou até mesmo evoluir para insuficiência cardíaca congestiva. O diagnóstico definitivo é feito por meio da visualização das alterações no exame ecodopplercardiográfico. No presente relato foi atendido em uma clínica particular do Rio de Janeiro, Brasil, um canino da raça buldogue francês de três meses de idade, sem sintomatologia clínica. Ao exame clínico constatou-se à ausculta cardíaca sopro sistólico em foco tricuspídeo e em foco pulmonar. Foram realizados exames complementares como: radiografia torácica, eletrocardiograma de repouso e ecodopplercardiograma, cujas as alterações permitiram o diagnóstico de estenose pulmonar e uma melhor avaliação da condição cardíaca do paciente. Iniciou-se o tratamento clínico com betabloqueador e posteriormente foi realizado o procedimento cirúrgico com a técnica da valvoplastia por balão. O exame clínico detalhado, principalmente à ausculta cardíaca de animais jovens, são de suma importância para a elaboração da suspeita clínica e conseqüentemente pesquisa diagnóstica. O objetivo do trabalho foi relatar o caso de um canino jovem com estenose da valva pulmonar submetido a tratamento clínico e cirúrgico, ressaltando a importância dos exames físico e complementares para o diagnóstico.

**Palavras-chave:** ausculta cardíaca, betabloqueador, má formação, cardiopatia congênita, ecodopplercardiograma



**How to cite:** Silva, B. R. S. A., Lemos, N. M. O., Santos, N. V. C., Barata, J. S., & Bendas, A. J. R. (2019). Pulmonary stenosis in a dog submitted to valvuloplasty: case report. *Brazilian Journal of Veterinary Medicine*, 41, e103019. doi: 10.29374/2527-2179.bjvm103019

**Financial support:** None.

**Conflict of interests:** No conflict of interests declared concerning the publication of this article.

**Received:** February 10, 2019.

**Accepted:** March 25, 2019.

The study was carried out at Instituto de Especialidades em Medicina Veterinária – IEMEV and Universidade Castelo Branco – UCB, Rio de Janeiro, RJ, Brasil.

### \*Correspondence

Bruno Ricardo Soares Alberigi da Silva  
Universidade Castelo Branco – UCB  
Avenida Brasil, 9727, Penha  
CEP 21030-000 - Rio de Janeiro (RJ), Brasil  
E-mail: bruno.alberigi@gmail.com

Copyright Silva et al. This is an Open Access article distributed under the terms of the Creative Commons Attribution Non-Commercial License which permits unrestricted non-commercial use, distribution, and reproduction in any medium provided the original work is properly cited.

## Introduction

Congenital heart diseases are characterized by cardiac morphological defects in embryonic development. It affects approximately 0.8% of the dogs, being the most common findings: pulmonary or aortic stenosis, ventricular septal defect and ductus arteriosus persistence (Schrope, 2015). Pulmonary and subaortic stenosis may occur associated followed by pulmonary stenosis with interventricular septum defect (Oliveira et al., 2011).

Pulmonary stenosis mainly affects young animals of the terrier or spaniel breeds. However, there are reports of its occurrence in brachycephalic dogs (Laborda-Vidal et al., 2016; Chetboul et al., 2018). The disease is characterized by a decrease in the pulmonary artery outflow, and may be classified as subvalvar, valvar or supravalvar stenosis (Strickland & Oyama, 2016). Although clinical signs such as exercise intolerance, syncope and other signs common to heart failure (CHF) may be present (Tilley & Goodwin, 2002), affected dogs are usually asymptomatic.

The cardiac auscultation is fundamental for the elaboration of the clinical suspicion and consequently the diagnosis once that is the simple exam that brings the physical problem to the surface. During the physical examination the main findings include cyanosis and ascites added to other signs of right congestive heart failure (CHF) (Tilley & Goodwin, 2002; MacDonald, 2006). The definitive diagnosis is made through the Doppler echocardiogram with visualization of morphological cardiac alterations (Boon, 2011).

The treatment is surgical, but when this is not possible, clinical treatment can be instituted to control clinical signs or even to slow down the progression of the disease (MacDonald, 2006; Locatelli et al., 2013). The clinical treatment consists in improving the cardiac output by the administration of beta-blocker, as along with other drugs used in the right CHF, according to its clinical presentation (Tilley & Goodwin, 2002; Strickland & Oyama, 2016). Balloon valvuloplasty is the surgical technique of choice for pulmonary stenosis. It is minimally invasive, it is guided by angiography and the balloon is inflated at the height of the pulmonary valve allowing its opening. The technique is contraindicated in cases with anomalous coronary arteries or with congestive heart failure (Strickland & Oyama, 2016).

The aim of this study was to report the case of a three months old French Bulldog with pulmonary valve stenosis undergoing surgical treatment, emphasizing the importance of clinical evaluation and complementary tests for diagnosis.

## Historical findings

A three months old male French bulldog, with no history of clinical signs was presented to a private veterinary practice in Rio de Janeiro, Brazil, for pediatric routine consultation. Clinical examination revealed heart murmur in the tricuspid and pulmonary focus, both graded as IV/VI, with no other alterations detected at clinical examination. Thoracic X-rays, electrocardiogram (EKG) and echocardiogram were requested for cardiac evaluation.

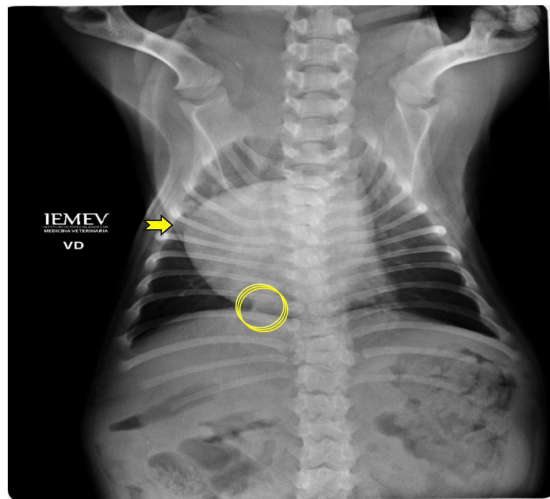
Radiography was performed in the lateral (right and left) and ventrodorsal positions, evidencing right atrioventricular increase and increase of caliber of caudal vena cava (Figure 1). The EKG revealed sinus rhythm, presence of deep "S" wave in lead D2 (Figure 2) and right axis deviation

In the ecodopplercardiogram in the apical cut four chambers a significant increase of the right atrium and concentric hypertrophy of the right ventricle (Figure 3) were observed. The color Doppler showed systolic turbulence inside the right atrium, indicating with severe tricuspid regurgitation (Figure 4). In short axis, at the level of the papillary muscles there was hypertrophy of the interventricular septum (1.05 cm) when examined by the M-mode of the left ventricle. In the cut of the right ventricular outflow tract, showing the pulmonary artery, stenosis of the pulmonary valve was observed, and in the right ventricular outflow tract there was presence of post-stenotic swirling (Figure 5). Spectral Doppler study showed pulmonary flow with a maximum velocity of 5.73 m/s (reference: <1.3 m/s) and a pressure gradient of 131.3mmHg (reference: 16mmHg) compatible with pulmonary artery (Figure 6). No coronary abnormality was detected.

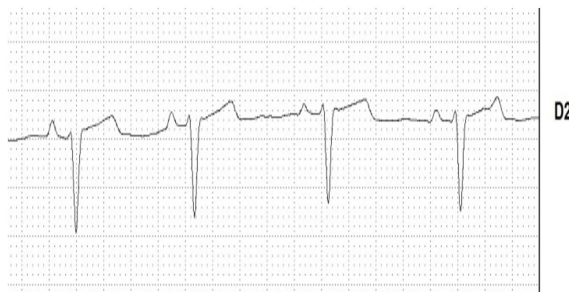
Based on the clinical findings and the diagnosis of pulmonary stenosis, was started the clinical treatment with the administration of beta-blocker, atenolol (0.5mg mg/kg) was instituted as treatment, and the patient was referred to a surgical center where the balloon valvuloplasty was performed.

The patient went through his first follow-up six months after the surgical procedure and at that point in time no clinical signs were present. The owners reported that the animal was more active than before surgery. In echocardiographic examination it was possible to notice a reduction of interventricular septal hypertrophy to values within normality (Figure 7).

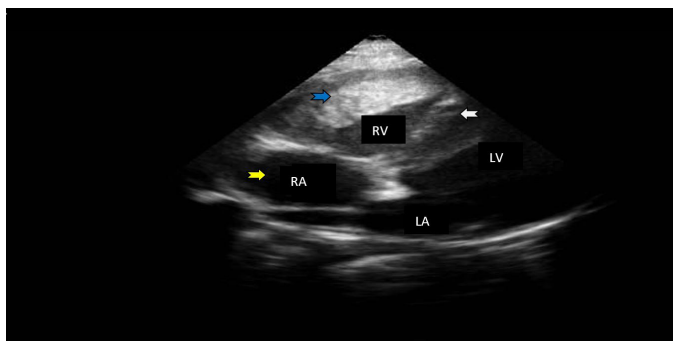
The pulmonary artery blood flow pressure gradient decreased significantly after the valvuloplasty procedure, falling to cardiological acceptable values (Figure 8). The presence of grade III / VI heart murmur in the tricuspid and pulmonary focus are perceived during the physical examination although no other sign of right heart failure is present.



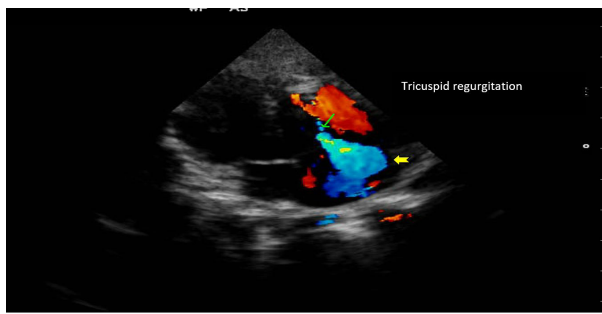
**Figure 1.** Thoracic X-ray image in the ventrodorsal projection with right atrioventricular enlargement, inverted "D" image (Arrow), and dilatation of the caudal cava vein (Circle) Source: courtesy of Dr. Denise Soares.



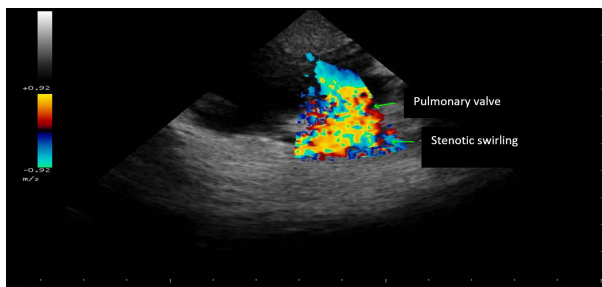
**Figure 2.** Electrocardiogram examination showing deep "S" waves and sinus rhythm. DII; N; 50mm/S.



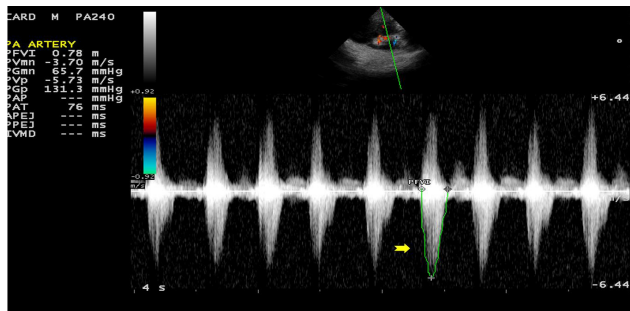
**Figure 3.** Echocardiographic image of left parasternal window, four-chamber apical section showing increased right atrium in the subjective analysis (yellow arrow), concentric hypertrophy of the right ventricle (blue arrow) and interventricular septal hypertrophy (white arrow). RA = right atrium; LA = left atrium; RV = right ventricle; LV = left ventricle.



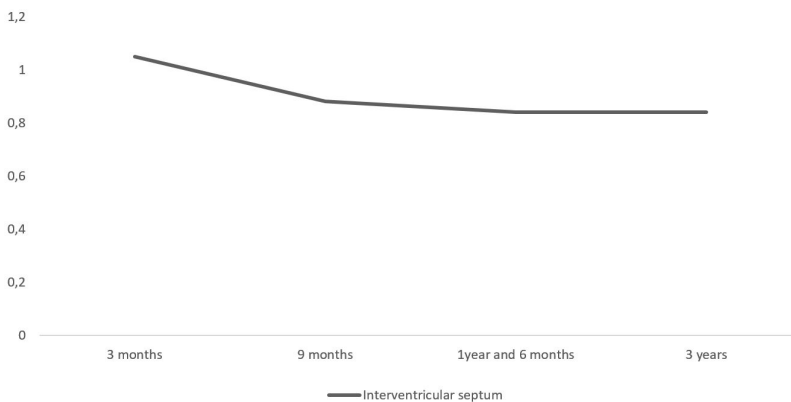
**Figure 4.** Doppler echocardiographic image, left parasternal window, four chamber apical section, to color Doppler study showing systolic turbulence inside the right atrium (arrow) indicating tricuspid valve regurgitation.



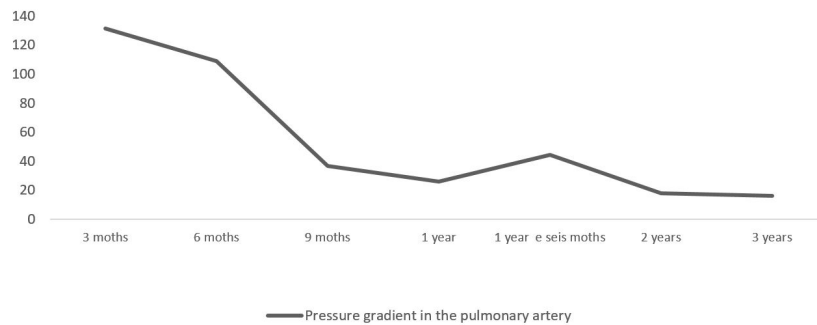
**Figure 5.** Doppler echocardiographic image, right parasternal window, at the right ventricular outflow tract, to the doppler study showing stenosis swirling.



**Figure 6.** Echocardiographic image of the left parasternal window, apical cut five chambers, spectral Doppler showing pulmonary flow with a maximum velocity of 5.73 m [s (arrow) and a pressure gradient of 131.1 mmHg, characterizing pulmonary stenosis.



**Figure 7.** Graph representing of the variation of the thickness of the interventricular septum in relation to the age of the patient after balloon valvuloplasty.



**Figure 8.** Graphic representing of the variation of the pressure gradient in the pulmonary artery, in relation to the age of the patient after balloon valvuloplasty.

After the first six months, with echocardiographic indexes of ventricular remodeling and pressure gradients within normal values (Figure 7 and 8), atenolol was progressively discontinued and the patient is monitored annually for the last three years. The patient has been asymptomatic from a cardiovascular point of view.

## Discussion

The suspicion of a congenital heart disease was raised during the auscultation in the pediatric routine evaluation. The presence of a heart murmur in the pulmonary focus during systole suggested the stenosis of the valve (Oliveira et al., 2011).

As pulmonary valve stenosis generates pressure overload in the right ventricle, concentric hypertrophy and consequent diastolic dysfunction, such as myocardial response, were expected changes (Bussadori & Pradelli, 2016). A greater force of contraction and greater ejection of blood from the right ventricle are secondary to hypertrophy and generate greater pressure within the right ventricle, causing blood regurgitation to the right atrium by overcoming resistance of the tricuspid valve, being these phenomena detected in physical examination as a systolic murmur in the tricuspid focus (Kristin, 2006). The Doppler echocardiogram was fundamental for the definitive diagnosis, since it allowed not only visualization of the pulmonary valve stenosis, but also signs of its hemodynamic repercussions such as: right ventricular hypertrophy; velocity of the pulmonary artery systolic flow and its pressure gradient increased, and tricuspid valve insufficiency (Strickland & Oyama, 2016).

The velocity of the pulmonary artery systolic flow determines the severity of the disease, and is generally increased, as observed in the present report. The increase in systolic flow of the pulmonary artery occurs due to the passage of blood through a reduced diameter ostium, characterizing valvular stenosis (Oliveira et al., 2011; Nishimura et al., 2018).

The right atrial enlargement observed on the chest x-ray and echocardiographic examination is explained by right ventricular blood flow to the right atrium, as well as the difficulty in passing blood from the right atrium to the right ventricle through diastolic dysfunction, leading to an overload of volume in the atrium and consequent dilatation of the same (Tilley & Goodwin, 2002).

The electrocardiogram usually shows no noticeable changes (Tilley & Goodwin, 2002). The deep "S" wave at D2 and the right axis deviation in the case may have occurred due to ventricular hypertrophy, resulting in a change in the vector of the ventricular activation process and may coexist with a discrete degree of right bundle branch block (Tilley & Goodwin, 2002; Oliveira et al., 2011).

Clinical treatment with atenolol, aimed to reduce myocardial oxygen consumption as well as the reduction of sympathetic tone and right ventricular contractility until the surgical procedure was performed (MacDonald, 2006; Francis et al., 2011).

The technique used in the present case, balloon valvuloplasty, is the technique of choice for pulmonary valve stenosis, performed in conjunction with cardiac catheterization, dilating the stenosed area with balloon insufflation (Treseder & Jung, 2017; Belanger et al., 2018). This technique reduces the pulmonary artery pressure gradient from 40 to 60%, improving the

clinical signs and in some situations the echocardiographic parameters, as observed in the report, where the thickness of the interventricular septum and the pressure gradient in the pulmonary artery decreased progressively over the years after balloon valvuloplasty (Bussadori et al., 2001; Locatelli et al., 2011; Strickland & Oyama, 2016).

In the follow-up of a year and a half, an increase of the pressure gradient inside the pulmonary artery was observed when compared to the previous examination, however on that day the patient was agitated during the exam. It is known that in agitated animals, an increase in heart rate occurs (Tilley & Goodwin, 2002), which influences the blood flow velocity in the pulmonary artery, directly influencing the pressure gradient (Boon, 2011).

After the surgical treatment, the pressure gradient was gradually normalized, making the use of atenolol unnecessary, and because of this it was progressively discontinued in order to avoid possible withdrawal reactions related to its sudden withdrawal, such as persistent tachycardia and myocardial ischemia (Sisson & Kittleson, 1988).

## Conclusion

The physical examination was fundamental to raise the suspicion of congenital cardiopathy, and the Doppler echocardiogram was definitive to achieve diagnosis. In the present report, the use of the balloon valvuloplasty technique, associated with previous clinical treatment was an effective approach that could be evidenced by an improvement in echocardiographic parameters and maintenance of the patient's welfare over time.

## References

- Belanger, C., Gunther-harrington, C. T., Nishimura, S., Oldach, M. S., Fousse, S. L., Visser, L. C., & Stern, J. A. (2018). High-pressure balloon valvuloplasty for severe pulmonar valve stenosis: a prospective observational pilot study in 25 dogs. *Journal of Veterinary Cardiology*, 20(2), 115-122. <http://dx.doi.org/10.1016/j.jvc.2018.01.001>. PMID:29459123.
- Boon, J. A. (2011). *Veterinary echocardiography* (2nd ed.). West Sussex: Wiley-Blackel.
- Bussadori, C., & Pradelli, D. (2016). Congenital cardiopathies. In V. Chetboul, C. Bussadori & E. Madron (Eds.), *Clinical echocardiography of the dog and cat* (1st ed., pp. 285-322). Missouri: Elsevier.
- Bussadori, C., DeMadron, E., Santilli, R. A., & Borgarelli, M. (2001). Balloon valvuloplasty in 30 dogs with pulmonic stenosis: effect of valve morphology and annular size on initial and 1-year outcome. *Journal of Veterinary Internal Medicine*, 15(6), 553-558. <http://dx.doi.org/10.1111/j.1939-1676.2001.tb01590.x>. PMID:11817060.
- Chetboul, V., Damoiseaux, C., Poissonnier, C., Lavennes, M., Bertrand, S., Borenstein, N., Behr, L., Pouchelon, J. L., Gouni, V., & Desquilbet, L. (2018). Specific features and survival of French bulldogs with congenital pulmonic stenosis: a prospective cohort study of 66 cases. *Journal of Veterinary Cardiology*, 20(6), 405-414. <http://dx.doi.org/10.1016/j.jvc.2018.09.001>. PMID:30526956.
- Francis, A. J., Johnson, M. J. S., Culshaw, G. C., Corcoran, B. M., Martin, M. W. S., & French, A. T. (2011). Outcome in 55 dogs with pulmonic stenosis that did not undergo ballon valvuloplasty or surgery. *The Journal of Small Animal Practice*, 52(6), 282-288. <http://dx.doi.org/10.1111/j.1748-5827.2011.01059.x>. PMID:21627655.
- Kristin A.M. (2006). Congenital heart diseases of puppies and kittens. *Veterinary Clinics: Small Animal Practice*, 36(3), 503-531. <https://doi.org/10.1016/j.cvsm.2005.12.006>
- Laborda-Vidal, P., Pedro, B., Baker, M., Gelzer, A. R., Dukes-McEwan, J., & Maddox, T. W. (2016). Use of ECG-gated computed tomography, echocardiography and setective angopgraphy in five dogs with pulmonic stenosis and aberrant coronary arteries. *Journal of Veterinary Cardiology*, 18(4), 418-426. <http://dx.doi.org/10.1016/j.jvc.2016.08.003>. PMID:27693045.
- Locatelli, C., Domenech, O., Silva, J., Oliveira, P., Sala, E., Brambilla, P. G., & Bussadori, C. (2011). Independent predictors of immediate and long-term results after pulmonary balloon valvuloplasty in dogs. *Journal of Veterinary Cardiology*, 13(1), 21-30. <http://dx.doi.org/10.1016/j.jvc.2010.10.003>. PMID:21277844.
- Locatelli, C., Spalla, I., Domenech, O., Sala, E., Brambilla, P. G., & Bussadori, C. (2013). Pulmonic stenosis in dogs: survival and risk factors in a retrospective cohort of patients. *The Journal of Small Animal Practice*, 54(9), 445-452. <http://dx.doi.org/10.1111/jsap.12113>. PMID:23889710.
- MacDonald, K. A. (2006). Congenital heart diseases of puppies and kittens. *Veterinary Clinics of North America: Small Animal Practice*, 36(3), 503-531. <http://dx.doi.org/10.1016/j.cvsm.2005.12.006>. PMID:16564411.
- Nishimura, S., Visser, L. C., Belanger, C., Oldach, M. S., Gunther-harrington, C. T., & Stern, J. A. (2018). Echocardiographic evaluation of velocity ratio, velocity time integral ratio, and pulmonary valve area in dogs with pulmonary valve stenosis. *Journal of Veterinary Internal Medicine*, 32(5), 1-9. <http://dx.doi.org/10.1111/jvim.15244>. PMID:30079482.

- Oliveira, P., Domenech, O., Silva, J., Vannini, S., Bussadori, R., & Bussadori, C. (2011). Retrospective review of congenital heart disease in 976 dogs. *Journal of Veterinary Internal Medicine*, 25(3), 477-483. <http://dx.doi.org/10.1111/j.1939-1676.2011.0711.x>. PMID:21418326.
- Schrope, D. P. (2015). Prevalence of congenital heart disease in 76,301 mixed-breed dogs and 57,025 mixed-breed cats. *Journal of Veterinary Cardiology*, 17(3), 192-202. <http://dx.doi.org/10.1016/j.jvc.2015.06.001>. PMID:26363941.
- Sisson, D., & Kittleson, M. D. (1988). Management of heart failure: principles of treatment, therapeutic strategies, and pharmacology. In P. Fox, D. Sisson & N. Moise (Eds.), *Textbook of canine and feline cardiology* (2nd ed., pp. 216-250). Philadelphia: W. B. Saunders.
- Strickland, K. N., & Oyama, M. A. (2016). Congenital heart disease. In F. W. K. Smith Jr, M. A. Oyama & M. Sleeper (Eds.), *Manual of canine and feline cardiology* (5th ed., pp. 218-238). Missouri: Elsevier.
- Tilley, L. P., & Goodwin, J. K. (2002). *Manual de cardiologia para cães e gatos* (3rd ed.). São Paulo: Roca.
- Treseder, J. R., & Jung, S. (2017). Balloon dilation of congenital supra-ventricular pulmonic stenosis in a dog. *Journal of Veterinary Science*, 18(1), 111-114. <http://dx.doi.org/10.4142/jvs.2017.18.1.111>. PMID:27297421.